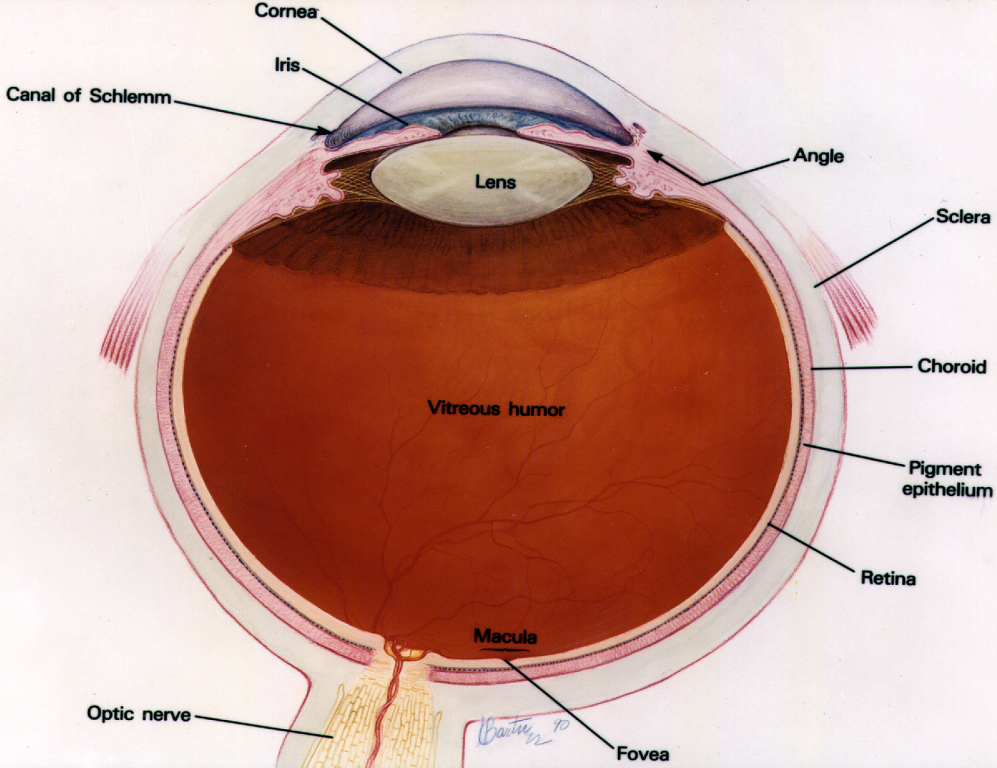
Cornea
Iris
Canal of Schlemm
Angle
Lens
Sclera
Choroid
Vitreous humor
Pigment epithelium
Retina
Macula
Optic nerve
Fovea